



Ex Vivo testing of a Ferromagnetic Detector for Evaluation of Bullets and Aneurysm Clips: A Potential Screening Device Prior to MR of Patients with Metal of Unknown Magnetic Properties.

Bryan A. Pukenas MD, Alexander C. Mamourian MD



Division of Neuroradiology, Department of Radiology
University of Pennsylvania Hospital, Philadelphia, PA

Purpose

MR imaging is presumed hazardous in many patients with retained bullets, shot, and some aneurysm clips. Even though most bullets¹ and aneurysm clips are safe to scan, radiologists should be hesitant to perform MR in patients with metal when the composition is unknown. The purpose of this study was to test the effectiveness of a commercial ferromagnetic metal detector, currently used for routine screening of patients who may be inadvertently carrying metal objects into the scanner, to discriminate nonferrous metal from ferrous ex vivo with the consideration of its potential use to screen for implanted metal.

Methods

Test objects consisted of various metallic objects from a personal collection which included nine aneurysm clips, two unfired bullets, one bullet found on a street, a penny, a small steel bolt, a Star-Edwards heart valve, and a paperclip. To determine ferrous properties of each object a magnet was placed over each device and objects demonstrating attraction were considered ferrous. Testing then was performed with a FerrAlert™ Halo Prescreen (Kopp Development, Jensen Beach, FL) ferromagnetic detector which was set to a sensitivity sufficient to detect a standard small paperclip. A deflection angle test was performed on the aneurysm clips in a 1.5 Tesla and 3.0 Tesla MR magnet according to the American Society for Testing and Materials guidelines² to determine their magnetic properties. Objects were passed through the FerrAlert™ Halo Prescreen detector in a subject's armpit to simulate an imbedded object.

Findings/Discussion

Data from the evaluation of seventeen objects are reported. All ferrous objects and none of the nonferrous objects were detected by the device (table 1). The two ferrous aneurysm clips studied that deflected greater than 80° in the 1.5T and 3.0T magnets were also detected by the device (table 2).

MRI in patients with implanted metallic objects has resulted in death³ but has also been reported to be safe in a subset of patients with bullets of unknown composition⁴. While imbedded projectiles from handgun and shotgun injury are nearly always nonferrous, concerns remain in cases where the object is in a vulnerable location because some tested bullets and steel shot have magnetic properties⁵.

The potential to detect implanted ferrous metal prior to entry into an MR unit would greatly reduce the potential for adverse outcomes as well as allowing many patients who are currently considered unsafe to scan to be imaged. The FerrAlert™ Halo Prescreen ferromagnetic detector emits no electromagnetic radiation and uses Hall effect sensors to detect ferrous objects which allows discrimination of metals magnetic properties⁶.

Summary/Conclusion

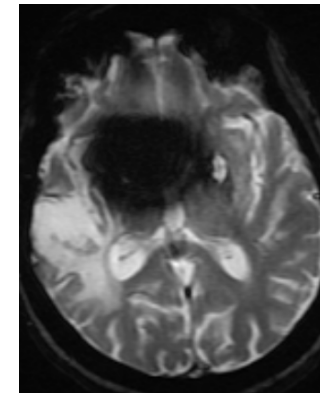
The FerrAlert™ Halo Prescreen device can distinguish clinically relevant nonferrous and equivalent ferrous objects ex vivo even when not in the immediate proximity of its hall effect sensors. A device using this principle has the potential to provide additional information regarding the nature of imbedded bullets that may allow some patients with retained projectiles to have MR exams. While we are not currently using the device for this purpose, we have demonstrated that its sensitivity supports further evaluation to this end.

References

- Teitelbaum GP, et al. Metallic ballistic fragments: MR Imaging safety and artifacts. *Radiology* 1990; 175:855-859.
- American Society for Testing and Materials. *Standard specification for the requirements and disclosure of self-closing aneurysm clips* In: Annual Book of ASTM standards, 1994. Philadelphia, Pa: American Society for Testing and Materials, 1994.
- Klucznik R, Carrier D, Pyka R, Haid R. Placement of a ferromagnetic intracerebral aneurysm clip in a magnetic field with a fatal outcome. *Radiology* 1993;187:855-856.
- Finitis SN, Falcone S, Green BA. MR of the spine in the presence of metallic bullet fragments: is the benefit worth the risk? *AJNR Am J Neuroradiol*. 1999 Feb;20(2):354-6.
- Kanal, letter to editor, *AJNR* 1999;20 (2):355.
- http://www.koppdevelopment.com/index-1.html#home_link



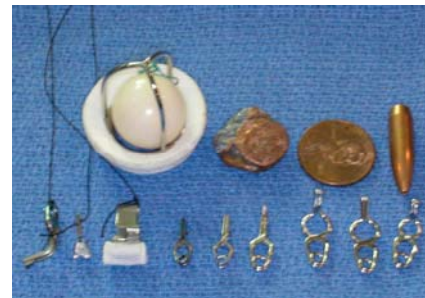FerrAlert™ Halo Prescreen ferromagnetic detector
<http://www.koppdevelopment.com/prescreen.html>



Axial Gradient Echo sequence demonstrating blooming artifact secondary to aneurysm clip.



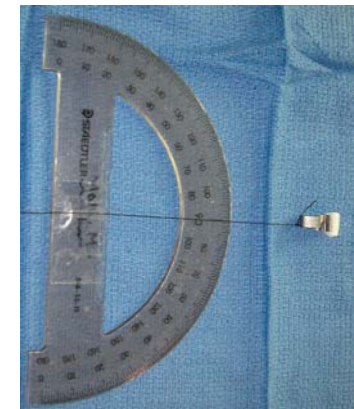
Items were considered ferrous if attracted to a test magnet



Sample of various objects tested

Object	Ferrous	FerrAlert™ detected
Paper Clip	YES	YES
Steel Bolt	YES	YES
Paper Clip	YES	YES
Sundt-Kee Encircling Clip	YES	YES
Ferrous Triangular Clip	YES	YES
1 Discharged Copper Bullet	NO	NO
2 unfired Copper Bullets (Casing Removed)	NO	NO
Starr-Edwards Silastic Ball Valve	NO	NO
7 nonferrous aneurysm clips	NO	NO
Penny	NO	NO

Table 1: Objects, Ferrous Property, and FerrAlert™ detected



Protractor used for angle of deflection test

Aneurysm Clip	Ferrous	Angle of Deflection 1.5T	Angle of Deflection 3.0T
Ferrous Triangular Clip	YES	83	86
Sundt-Kee Encircling Clip	YES	84	88
7 nonferrous aneurysm clips	NO	0	0

Table 2: Aneurysm clip and angle of deflection