

Clinical Note

Size "H" Oxygen Cylinder: Accidental MR Projectile at 1.5 Tesla

Patrick M. Colletti, MD

The risks of ferromagnetic compressed gas cylinders becoming projectiles in an MR environment are well known (1,2). The recent death of a child from such an incident reinforces the potential for disaster (3).

Key Words: MR safety; MR projectile; oxygen cylinder MR projectile; oxygen cylinder safety; ferromagnetic projectile
J. Magn. Reson. Imaging 2004;19:141-143.
 © 2003 Wiley-Liss, Inc.

CASE REPORT

A 47-YEAR-OLD FEMALE hospital inpatient with stage 4 breast cancer presented with back pain and confusion. She was sent to a free standing, hospital-associated MR center for thoracic spine, lumbar spine, and brain MR. A 1.5-Tesla unshielded system (Horizon LX; General Electric, Milwaukee, WI) was used. She entered the magnet headfirst. Due to her confused state, she was sedated with 1.0 mg of lorazepam given intravenously. She was monitored with a pulse oximeter (OmniTrak; Invivo Research, Inc., Orlando, FL). After four sequences, her pulse increased from 97 to 113 bpm and her oxygen saturation decreased from 78% to 68%.

Due to the patient's reduced O₂ saturation, the decision was made to remove the patient from the magnet. As the technologist and technologist assistant were initiating the removal of the patient, the patient's physician wheeled a large size "H" oxygen cylinder into the scanner room. The fully-pressurized, 130-cm high, 22.8-cm diameter "H"-type cylinder holds 6500 liters of oxygen at 2015 psi. Fully loaded, with its wheeled cart, it has a total mass of 80.6 kg. As the cylinder passed to the right of the foot of the imaging table, it was suddenly pulled toward the magnet. The technologist assistant, also at the right of the table, was barely able to dodge the incoming projectile as he moved toward the table to avoid direct impact. He escaped with several 10 cm superficial abrasions and a minor lateral contusion to his left arm. He had full range of motion without pain.

The flow regulator (Fig. 1) was sheared off of the cylinder (Fig. 2) and the cylinder impaled the scanner cowling at the one o'clock position (Fig. 3). The cylinder oscillated precariously, pivoting on the point of impalement. The physician and technologist were able to help the technologist assistant move past the nearly stable cylinder. At that point, in order to stabilize the cylinder and extract the uninjured but hypoxic patient, the chief technologist decided to perform an emergency ramp down of the system. The system ramped down to a negligible field in less than two minutes. With this "controlled quench," helium rapidly escaped via the overhead safety vent. The vent cap was damaged during this process and required replacement prior to cryogen refill. The in-room oxygen level monitor did not detect reduced oxygen levels. Within two minutes of the incident, as two assistants controlled and carefully removed the cylinder, the patient was removed from the magnet. She responded rapidly to oxygen administration.

Damages and costs included:

1. A 15-cm hole in the magnet cowling (Fig. 3); the cowling had to be replaced.
2. The 1600-lb gradient coils were displaced 1 cm and were rotated slightly; special tools were required for adjustment.
3. The scanning table was damaged; replacement was required, at a cost of \$8000.
4. The quenched magnet required an emergency fill of 600 liters of liquid helium (five flasks of 120 liters each), at a total cost of \$10,000.
5. Emergency after-hours service: 60 person-hours; at a cost of \$93,000.
6. Use of the scanner was lost for 34 hours.

DISCUSSION

Gas-filled cylinders present potential hazards, including gas-propulsive missile impaction, explosion, and fire. Ferromagnetic gas cylinders are especially dangerous in a magnetic environment, where they can be uncontrollably accelerated, creating a severe impact. Thus, a safety program for gas tanks in the MR environment includes procedures and training in the appropriate handling of cylinders and their exclusion from magnetic attraction. Indeed, many sites use in-line gas ports to avoid mobile oxygen cylinders entirely.

Department of Radiology, University of Southern California, Keck School of Medicine, Los Angeles, California.

*Address reprint requests to: P.M.C., LAC+USC Imaging Science Center, 1744 Zonal Avenue, Los Angeles, CA 90033. E-mail: colletti@usc.edu

Received November 18, 2002; Accepted May 15, 2003.

DOI 10.1002/jmri.10431

Published online in Wiley InterScience (www.interscience.wiley.com).




Figure 1. The flow regulator that was sheared off of the cylinder and the nonferromagnetic valve handle that fragmented upon impact with the table.



Figure 2. The size "H" oxygen cylinder after the regulator was sheared off. Note the scrapes on the cylinder and the bent beam on the cart.

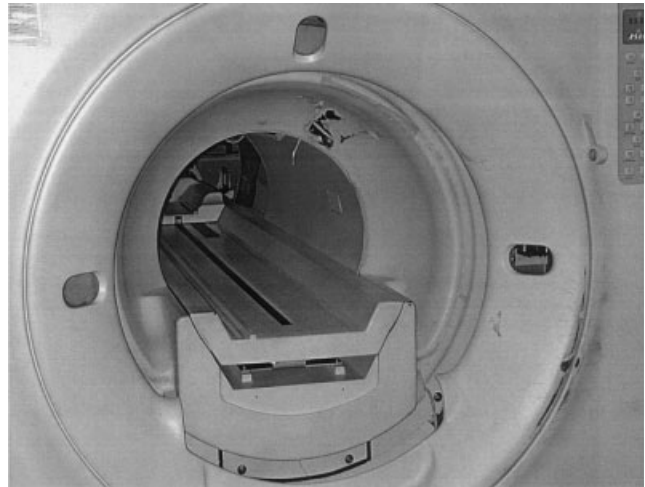


Figure 3. This 15-cm hole in the magnet cowling required the replacement of the cowling.

Magnetic projectile events require an appropriate response (4). Since this event occurred, we instituted major policy changes (5–8). All oxygen tanks have been replaced with nonferromagnetic cylinders. Due to the possibility of an erroneous cylinder exchange in the future, all cylinders are also tethered to the ground. All visiting personnel are required to complete and sign a one-page screening form covering potential risks to the visitor and others (9).

This event occurred in spite of our knowledge of the fatal MR oxygen-cylinder accident reported in 2001 (3). Indeed, that event was preceded by an apparently similar nonfatal incident at that same facility (4). Specifically, this incident is the result of two major errors that occurred sequentially. First, the introduction into an MRI environment of a large ferromagnetic object (such as an "H" cylinder on a wheeled cart) created a substantial risk. This error, in turn, set the stage for an inexperienced visiting physician to erroneously assume that the magnet was not at field, and that it would be safe to move this wheeled cylinder into the magnet room. On two occasions immediately prior to the projectile event, before this physician had attended to the patient, the MR technologist had verbally advised this physician of the magnetic field.

Gas cylinders remain a potential hazard in the MRI environment. Indeed, we were extremely fortunate that no one was severely injured in this event. Appropriate policies and discipline are essential to avoid such deadly and expensive gas cylinder accidents.

REFERENCES

1. Chaljub G, Kramer LA, Johnson III RF, Johnson RF, Jr, Singh H, Crow WN. Projectile cylinder accidents resulting from the presence of ferromagnetic nitrous oxide or oxygen tanks in the MR suite. *AJR Am J Roentgenol* 2001; 177:27–30.
2. Landrigan C. Preventable deaths and injuries during magnetic resonance imaging. *N Engl J Med* 2001;345:1000–1001.

3. Chen DW. Boy, 6, dies of skull injury during MRI; oxygen tank becomes fatal missile in hospital. *New York Times*; July 31, 2001. p B1, 5.
4. Department of Health, State of New York. Health department fines Westchester Medical Center \$22,000 for its failure to ensure patient safety during MRI procedures. Six-year-old patient fatally injured following tragic incident in medical center's MRI suite. Albany: State of New York Department of Health; September 28, 2001.
5. Rogers LF. MR safety: better safe than sorry. *AJR Am J Roentgenol* 2002;178:1311-1311.
6. Kanal E, Borgstede JP, Barkovich, et al. American College of Radiology white paper on MR safety. *AJR Am J Roentgenol* 2002;178:1335-1347.
7. Shellock FG, Crues JV. Commentary: MR safety and the American College of Radiology white paper. *AJR Am J Roentgenol* 2002;178:1349-1352.
8. Shellock FG. *Magnetic resonance safety*. Salt Lake City: Amirsys, Inc.; 2003.
9. Institute for Magnetic Resonance Safety, Education, and Research (IMRSER). *Magnetic resonance screening form for individuals*. <http://www.imrser.org/>.